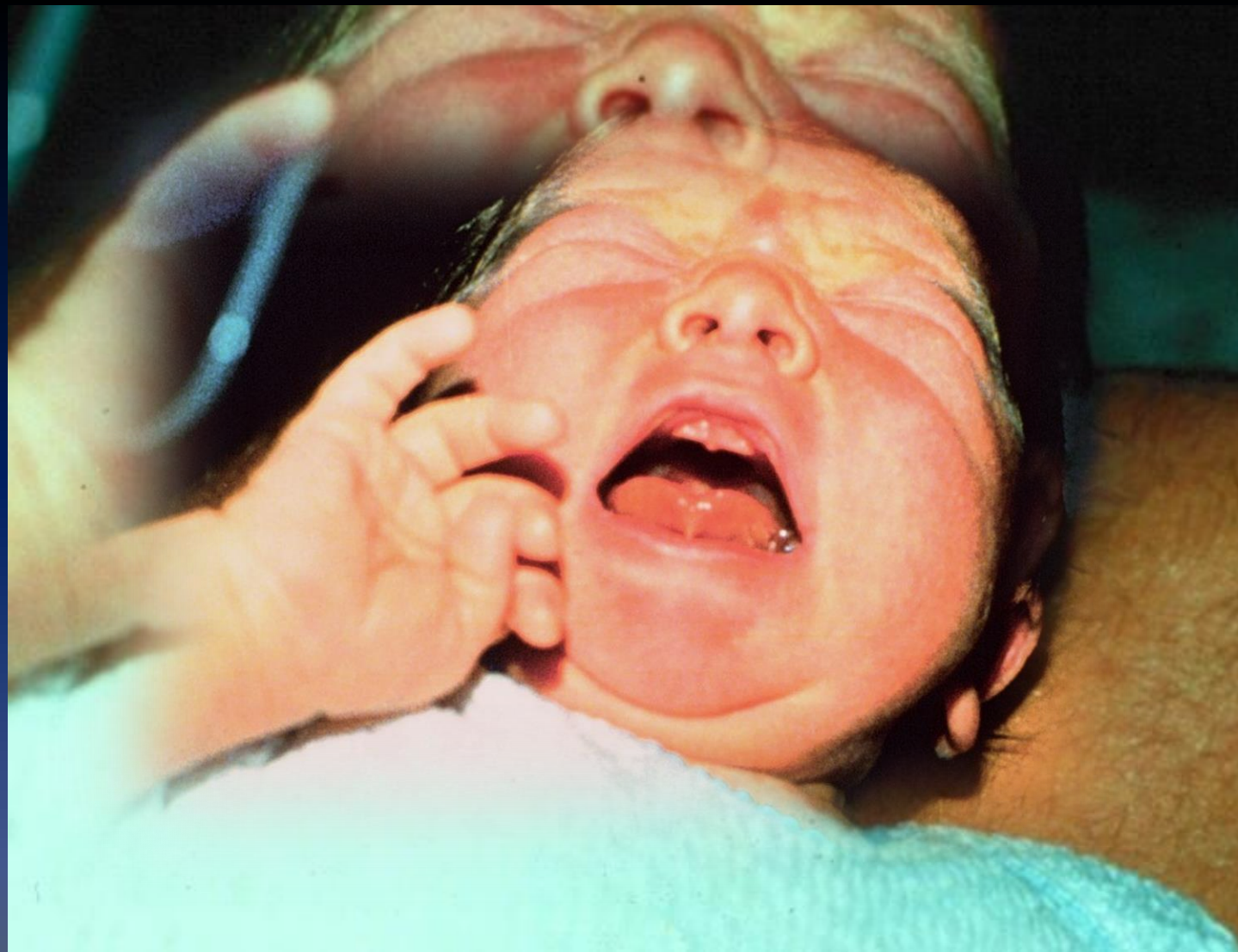



©Alison K. Hazelbaker, PhD, IBCLC, FILCA



- 1
- 2
- 3
- S
- C
- F
- f1
- f2
- f3
- f4
- f5
- f6
- f7
- A
- a1
- a2
- a3
- a4
- a5
- S
- B
- Q

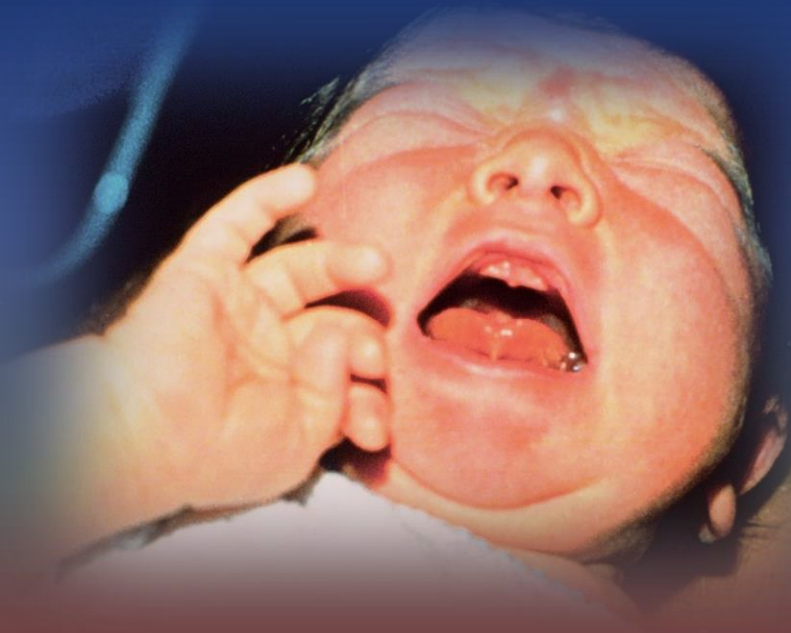THE HAZELBAKER ASSESSMENT TOOL FOR LINGUAL FRENULUM FUNCTION

Screening

Assessment

Classification

Distinctions



1

2

3

S

C

F

f1

f2

f3

f4

f5

f6

f7

A

a1

a2

a3

a4

a5

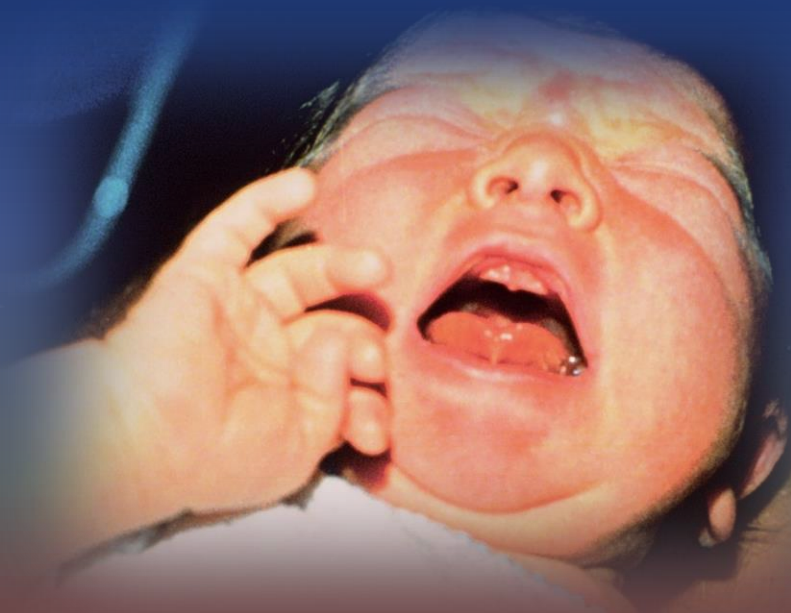S

B

Q



Assessment Tool for Lingual Frenulum Function



Assessment Tool for Lingual Frenulum Function (ATLFF)
© Alison K. Hazellbaker, PhD, IBCLC April 21, 2012

Mother's name: _____
Baby's name: _____
Baby's age: _____
Date of assessment: _____

FUNCTION ITEMS	
Lateralization	Cupping of tongue
2 Complete	2 Entire edge, firm cup
1 Body of tongue but not tongue tip	1 Side edges only, moderate cup
0 None	0 Poor OR no cup
Lift of tongue	Peristalsis (progressive contraction)
2 Tip to mid-mouth	2 Complete anterior to posterior (originates at tip)
1 Only edges to mid-mouth	1 Partial, originating posteriorly
0 Tip stays at alveolar ridge OR tip rises only to mid-mouth with jaw closure AND/OR mid-tongue dimples	0 None OR Reverse peristalsis
Extension of tongue	Sublingual folds
2 Tip over lower lip	2 Sublingual folds present
1 Tip over lower gum only	1 Sublingual folds present
0 Neither of the above OR tip does not touch lower lip OR tongue humps (dimpling)	0 Frequent OR with each suck
Speed of anterior tongue	
2 Complete	
1 Little OR partial	
0 Little OR none	
APPEARANCE ITEMS	
Appearance of tongue when lifted	Elasticity of lingual frenulum
2 Round OR square	2 Very elastic (excellent)
1 Slight click in tip apparent	1 Moderately elastic
0 Heart shaped	0 Little OR no elasticity
Length of lingual frenulum when tongue lifted	Attachment of lingual frenulum to tongue
2 More than 1 cm OR absent frenulum	2 Posterior to tip
1 1 cm	1 At tip
0 Less than 1 cm	0 Notched OR under the mucosa at the tongue base
Attachment of lingual frenulum to inferior alveolar ridge	
2 Attached to floor of mouth OR well below ridge	
1 Attached just below ridge	
0 Attached to ridge	

ASSESSMENT TOOL FOR LINGUAL FRENULUM FUNCTION

Screening Tool

1
2
3
S
C
F
f1
f2
f3
f4
f5
f6
f7
A
a1
a2
a3
a4
a5
S
B
Q

SCREENING WITH THE HATLFF

In Action:
Screening with the Assessment Tool for
Lingual Frenulum Function

1

2

3

S

C

F

f1

f2

f3

f4

f5

f6

f7

A

a1

a2

a3

a4

a5

S

B

Q



Function



Seven Items

1

2

3

S

C

F

f1

f2

f3

f4

f5

f6

f7

A

a1

a2

a3

a4

a5

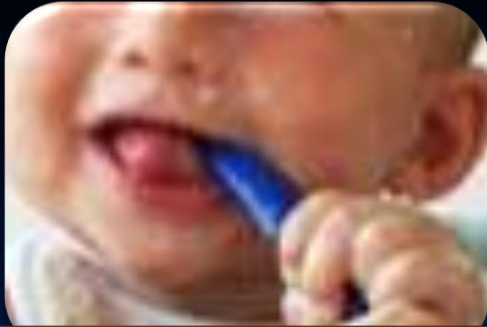S

B

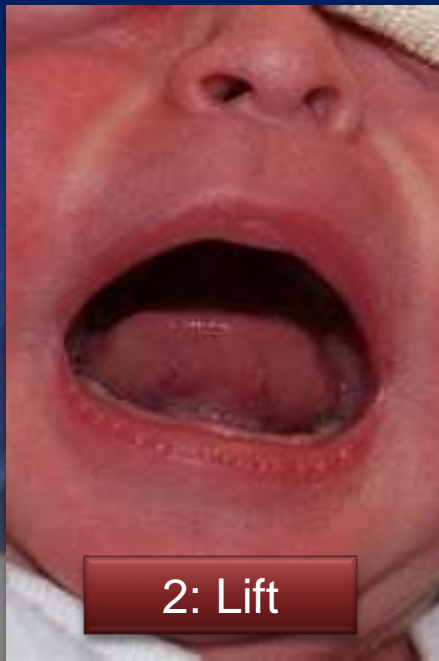Q



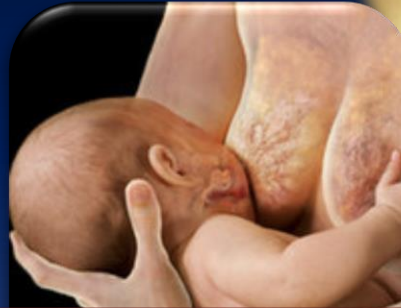Function



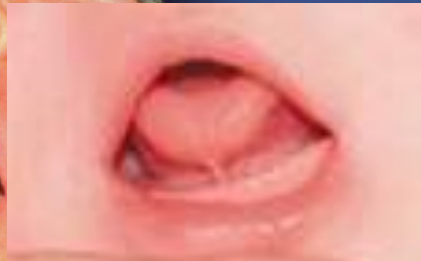1: Lateralization



2: Lift



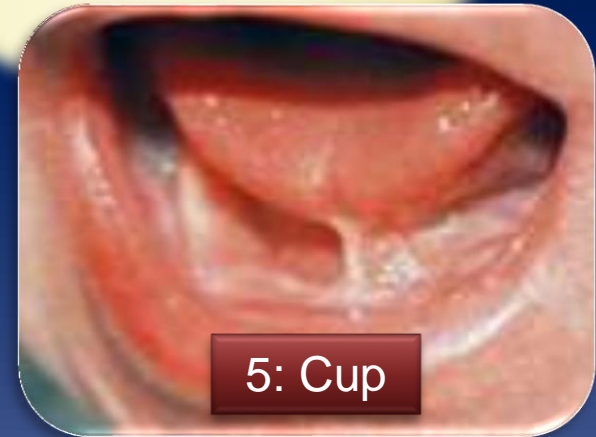6: Progressive Tongue Contraction



3: Extension/Dimple



7: Snap-back



5: Cup



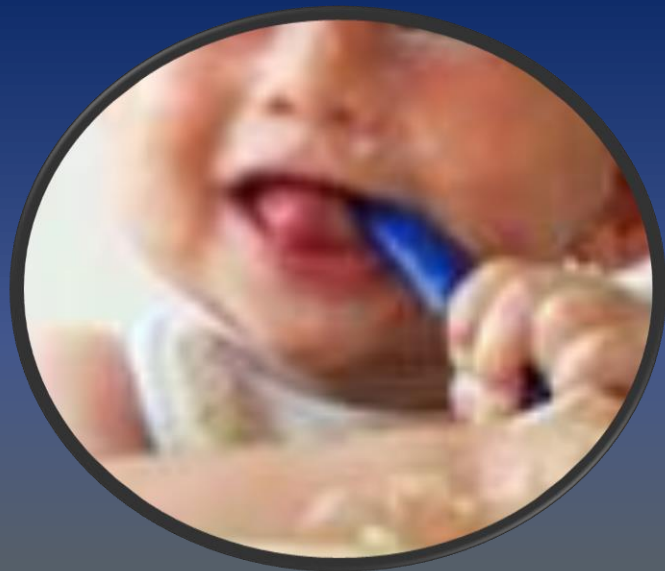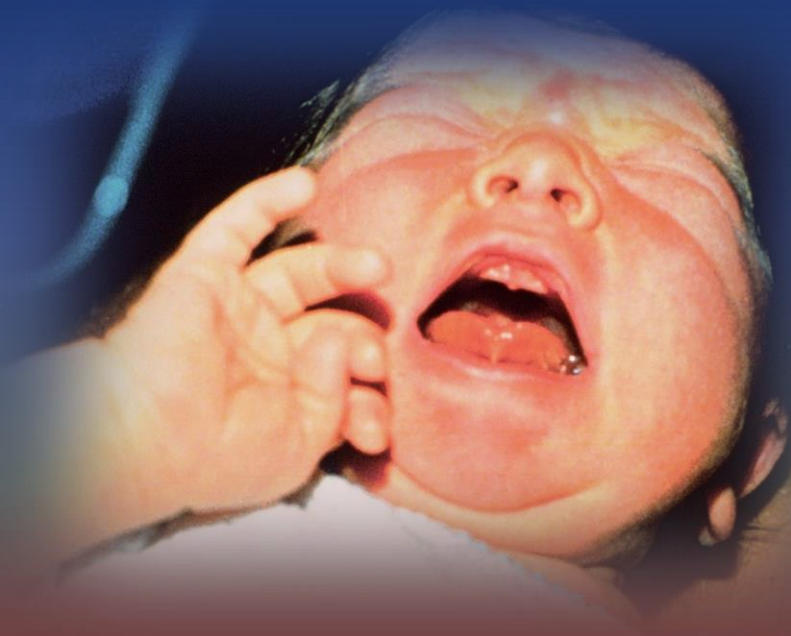4: Spread

Lateralization

2: Complete

1: Body of tongue but not tongue tip

0: None



1

2

3

S

C

F

f1

f2

f3

f4

f5

f6

f7

A

a1

a2

a3

a4

a5

S

B

Q

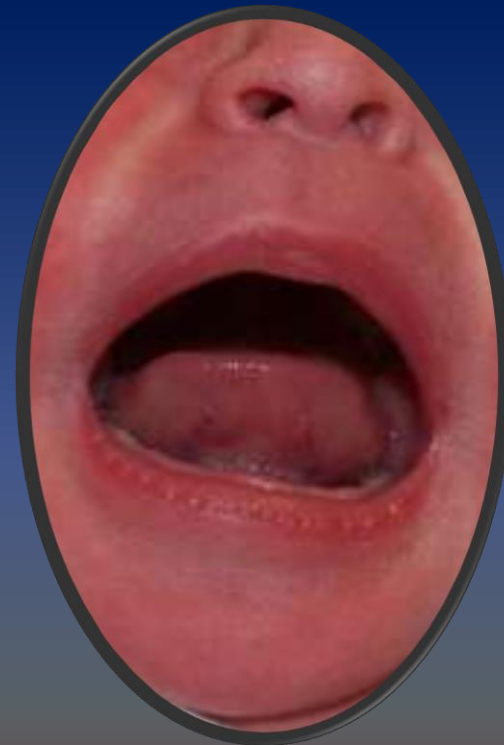
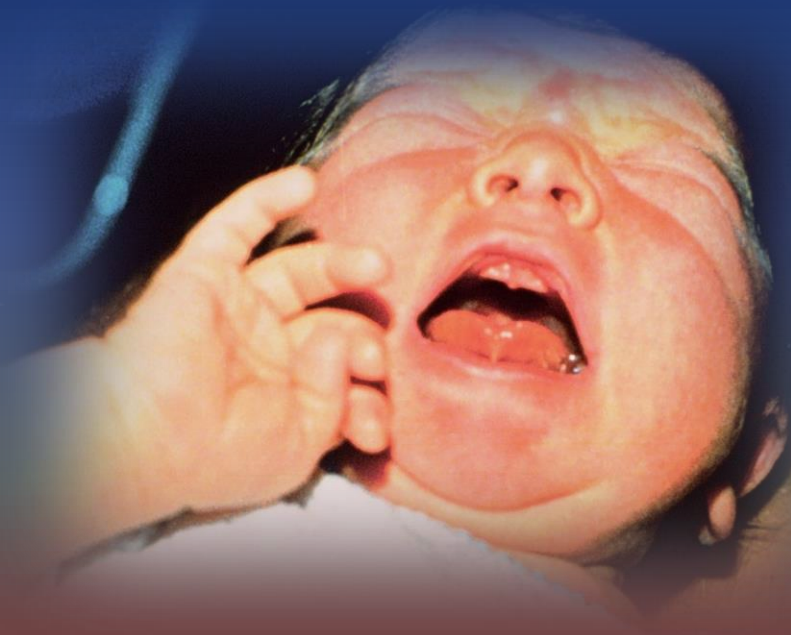
Lift

2: Tip to mid-mouth

1: Only edges to mid-mouth

0: Tip stays at alveolar ridge OR rises only to mid-mouth with jaw closure AND/OR mid-tongue dimples

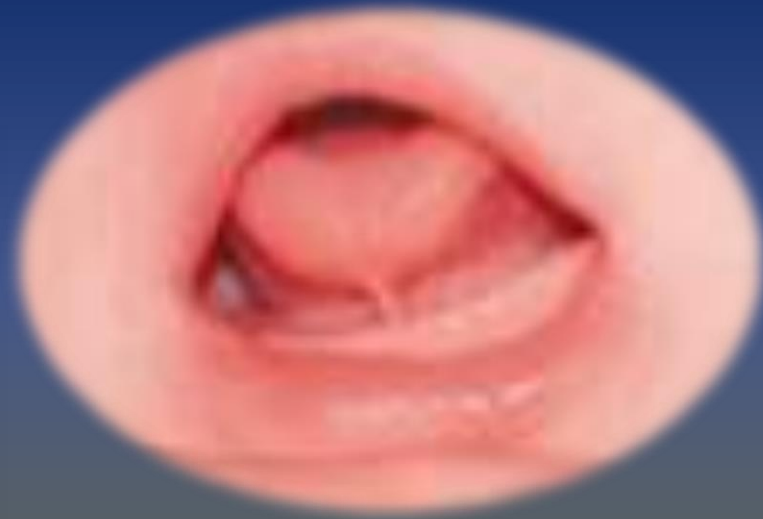


Extension

2: Tip over lower lip

1: Tip over lower gum only

0: Neither of the above OR anterior or mid-tongue humps AND/OR dimples

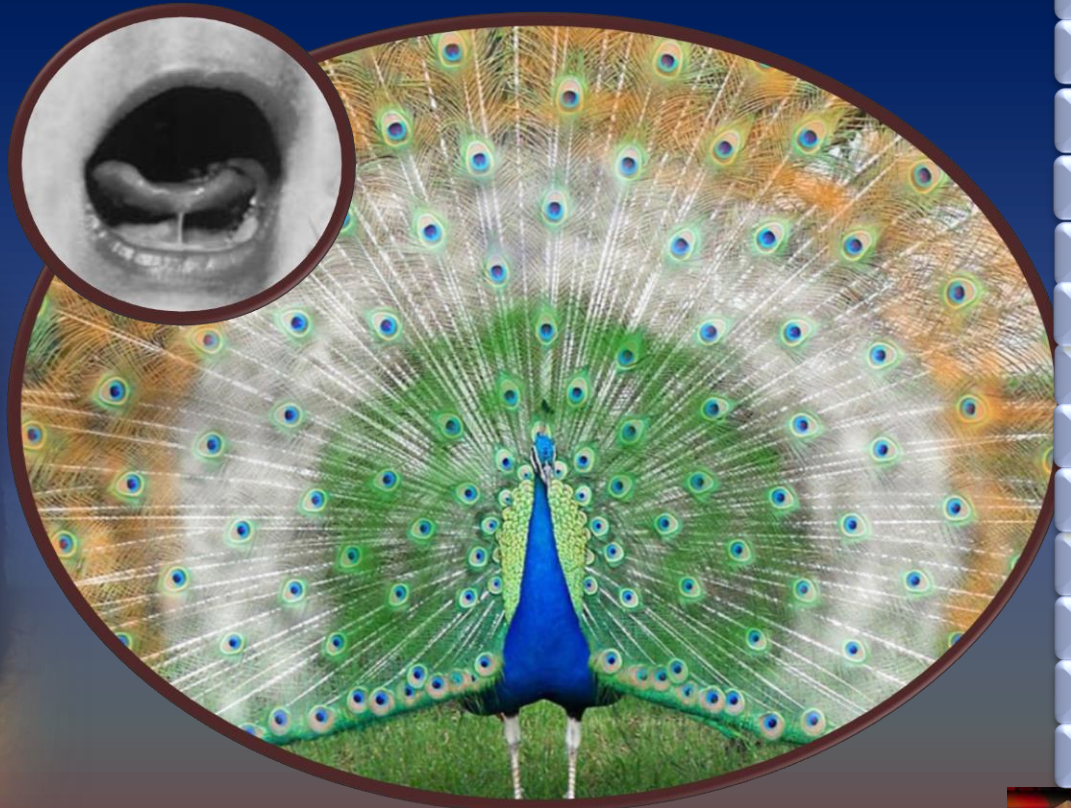
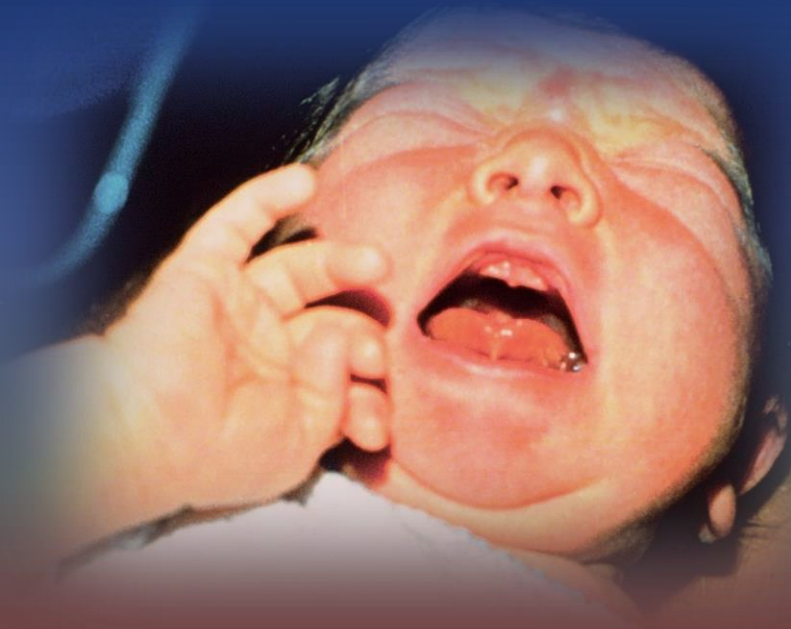

Spread of Anterior Tongue

2: Complete

1: Moderate OR partial

0: Little OR None

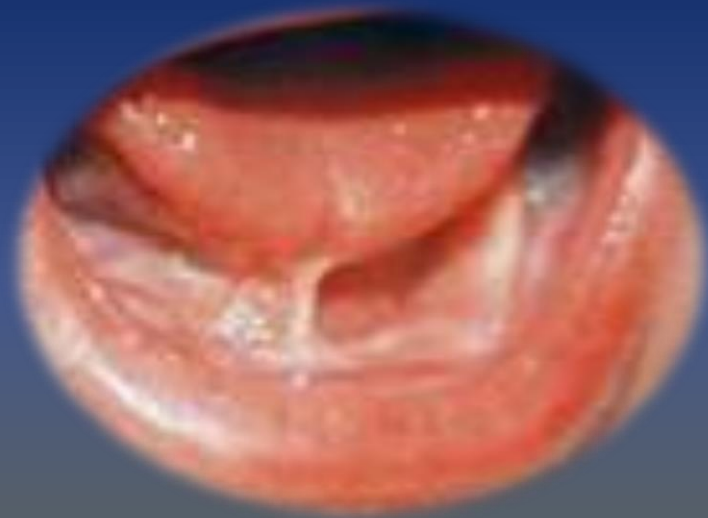


Cupping of Tongue

2: Entire edge, firm cup

1: Side edges only, moderate cup

0: Poor OR no cup



1

2

3

S

C

F

f1

f2

f3

f4

f5

f6

f7

A

a1

a2

a3

a4

a5

S

B

Q

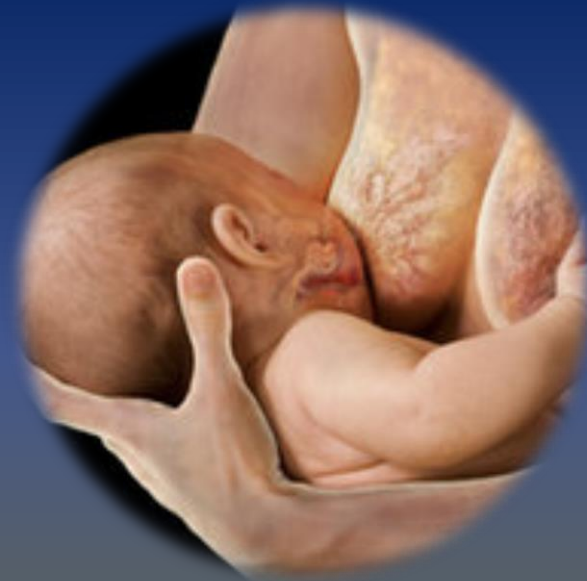

Peristalsis (progressive contraction)

2: Complete anterior to posterior (originates at tip)

1: Partial: originating posterior to tip

0: None OR Anterior thrusting



1

2

3

S

C

F

f1

f2

f3

f4

f5

f6

f7

A

a1

a2

a3

a4

a5

S

B

Q

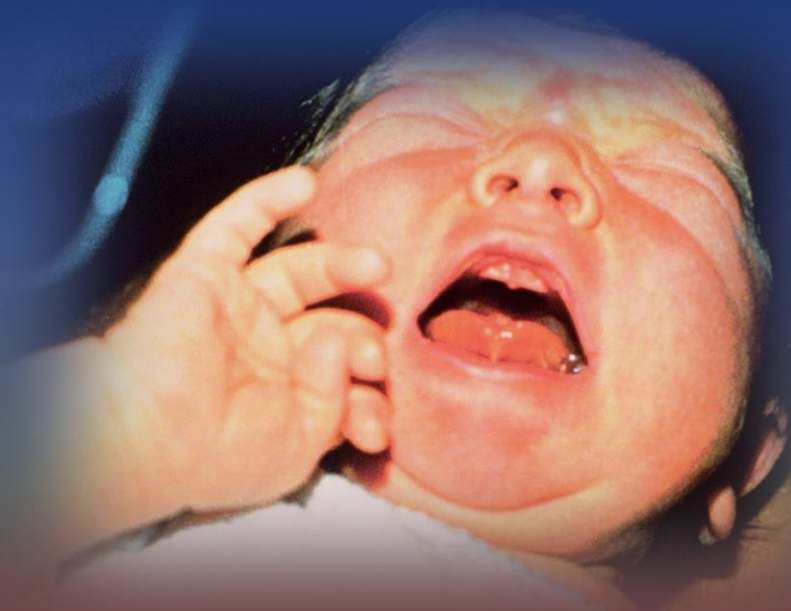


Snap Back

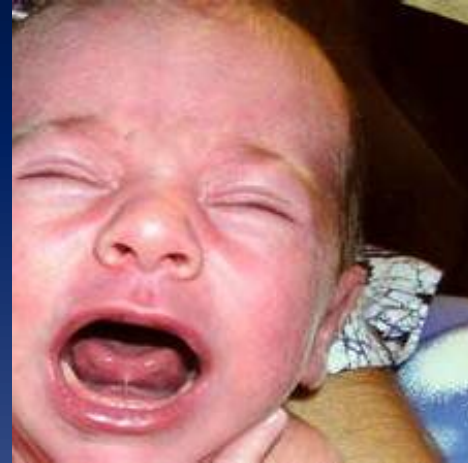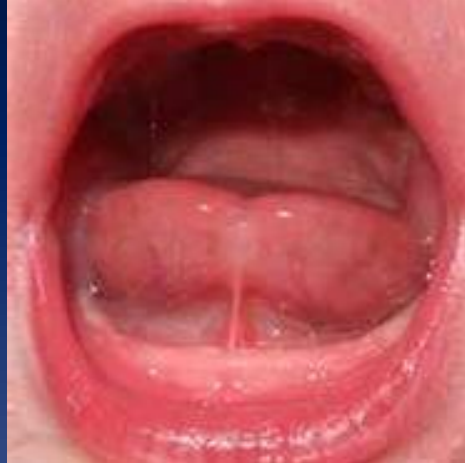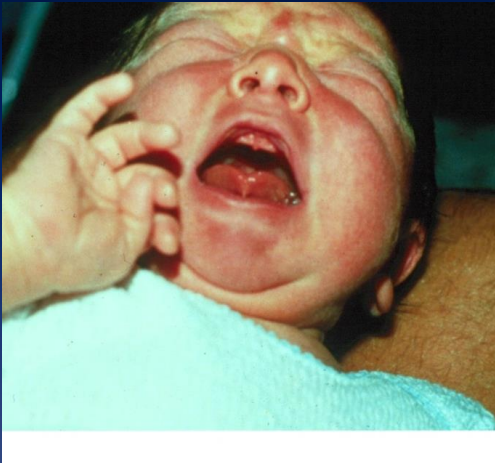2: None

1: Periodic

0: Frequent OR with each suck



Appearance



Five Items

1

2

3

S

C

F

f1

f2

f3

f4

f5

f6

f7

A

a1

a2

a3

a4

a5

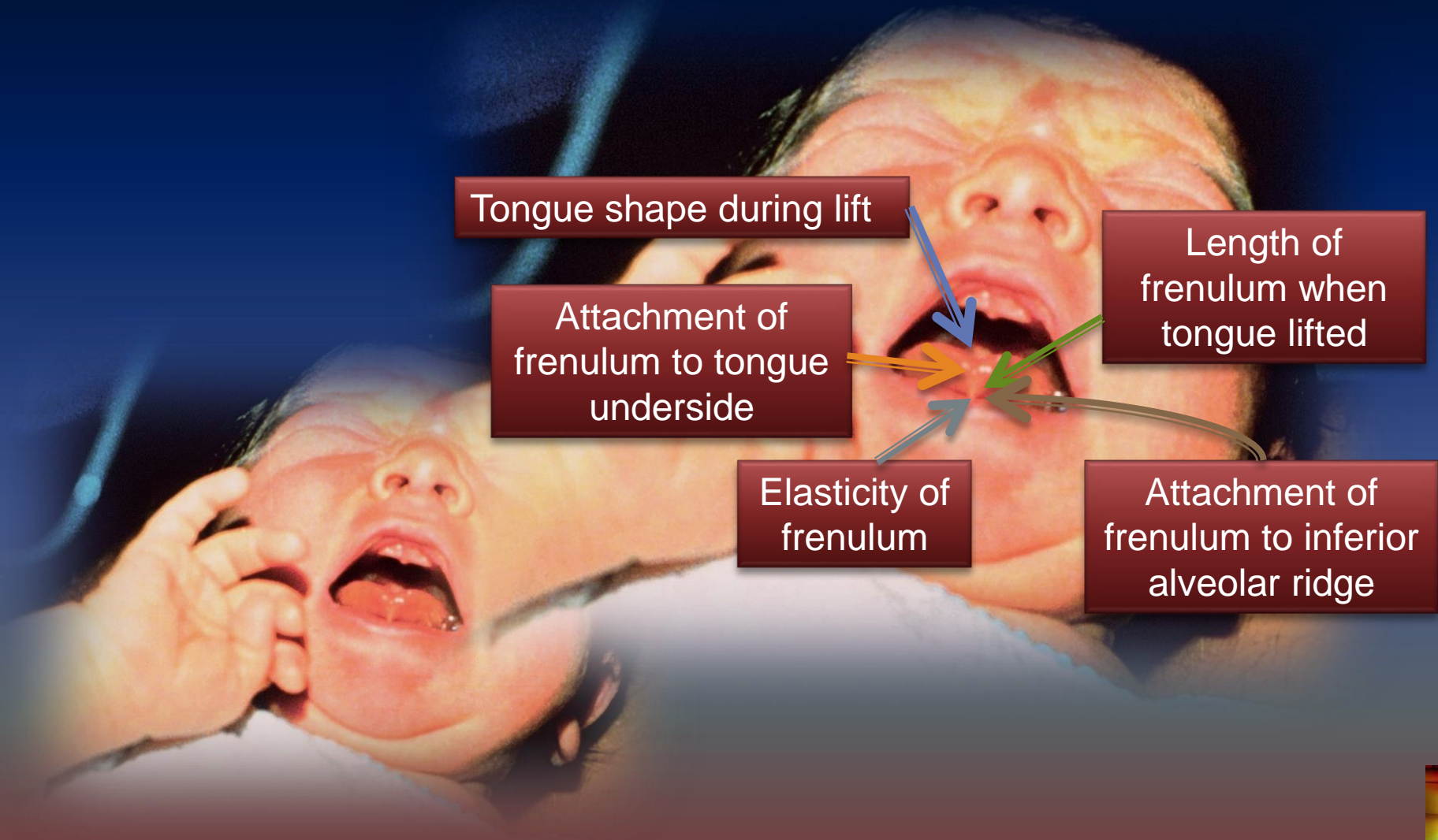
S

B

Q



Appearance



1

2

3

S

C

F

f1

f2

f3

f4

f5

f6

f7

A

a1

a2

a3

a4

a5

S

B

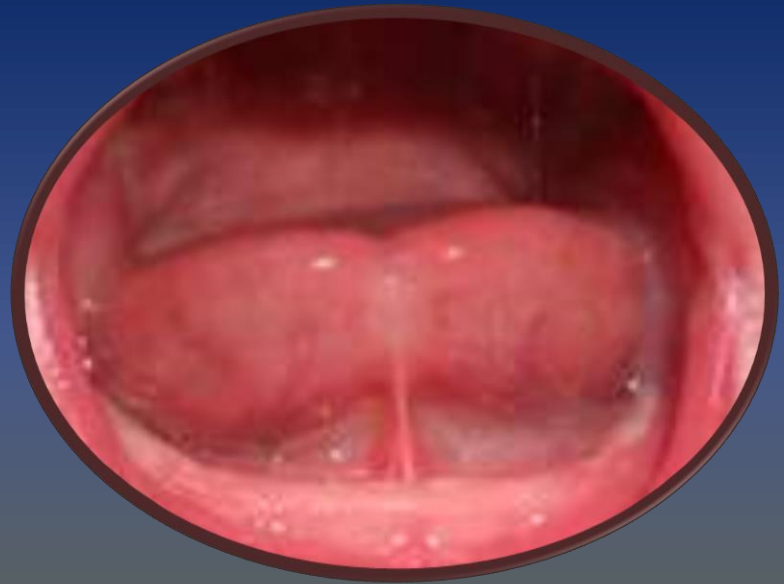
Q

Appearance of Tongue when Lifted

2: Round OR square

1: Slight cleft in tip apparent

0: Heart shaped



1

2

3

S

C

F

f1

f2

f3

f4

f5

f6

f7

A

a1

a2

a3

a4

a5

S

B

Q

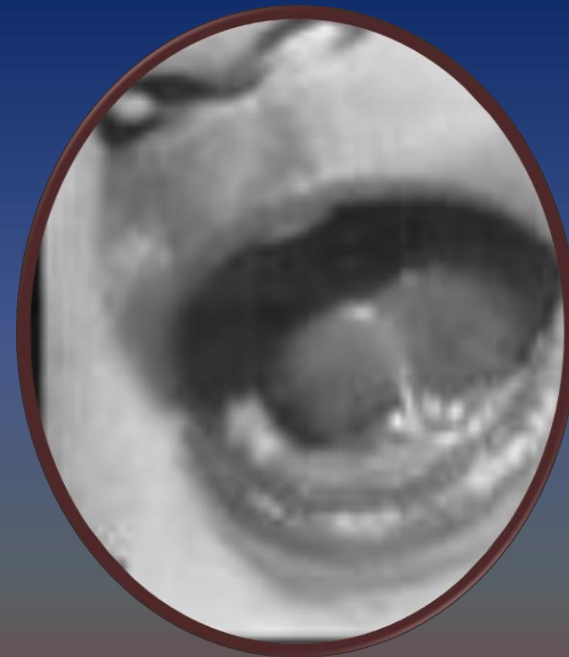
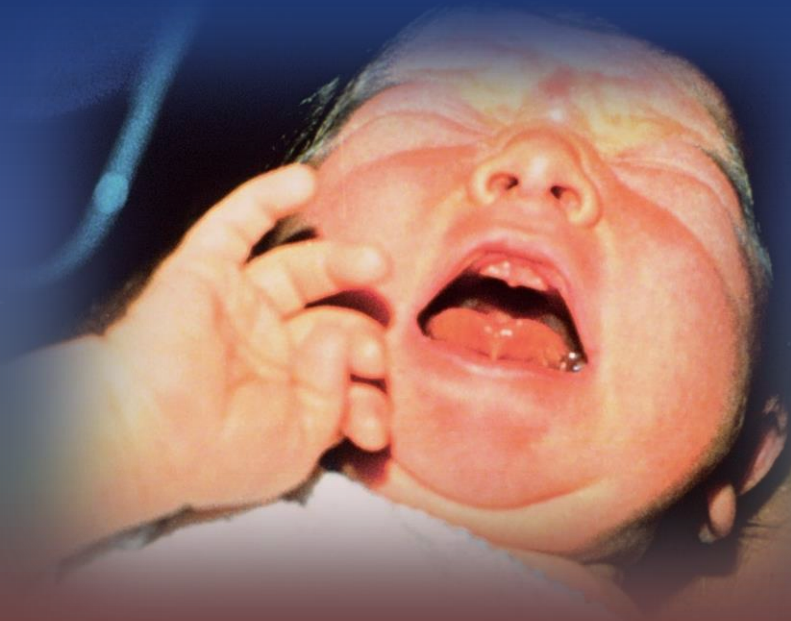

Length of Lingual Frenulum When Tongue Lifted

2: More than 1 cm OR absent frenulum

1: 1 cm

0: Less than 1 cm

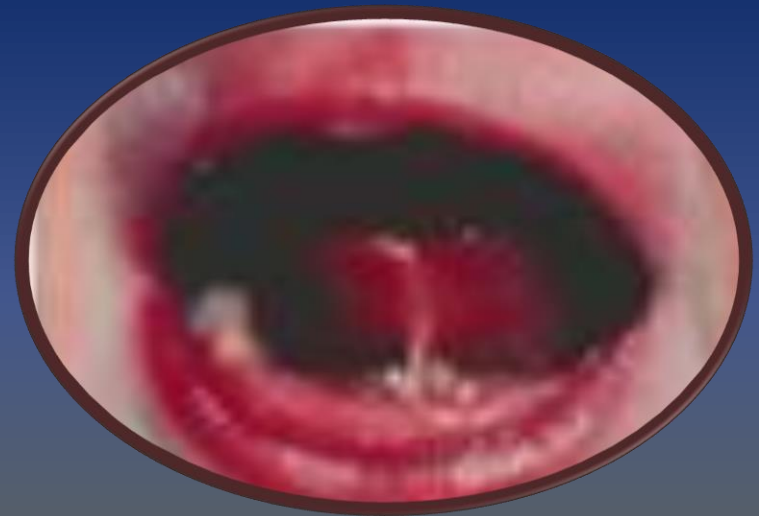

Elasticity of Lingual Frenulum

2: Very elastic (excellent)

1: Moderately elastic

0: Little OR no elasticity



1

2

3

S

C

F

f1

f2

f3

f4

f5

f6

f7

A

a1

a2

a3

a4

a5

S

B

Q

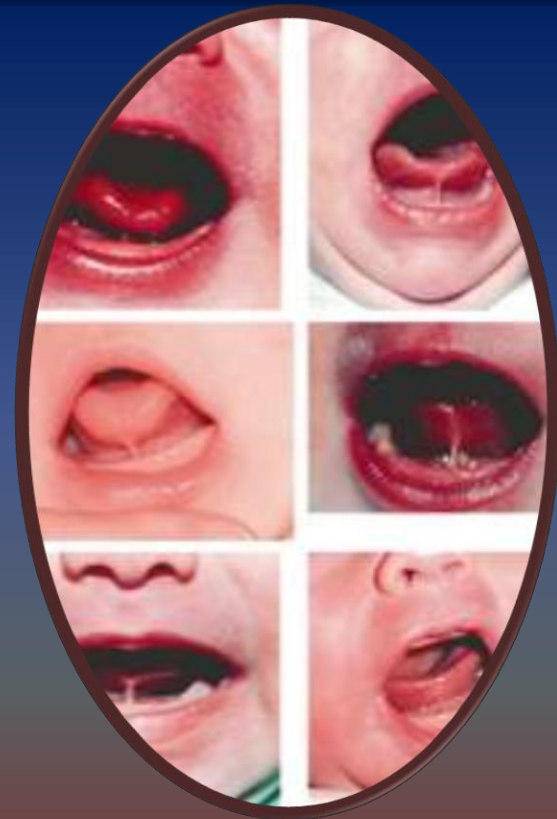
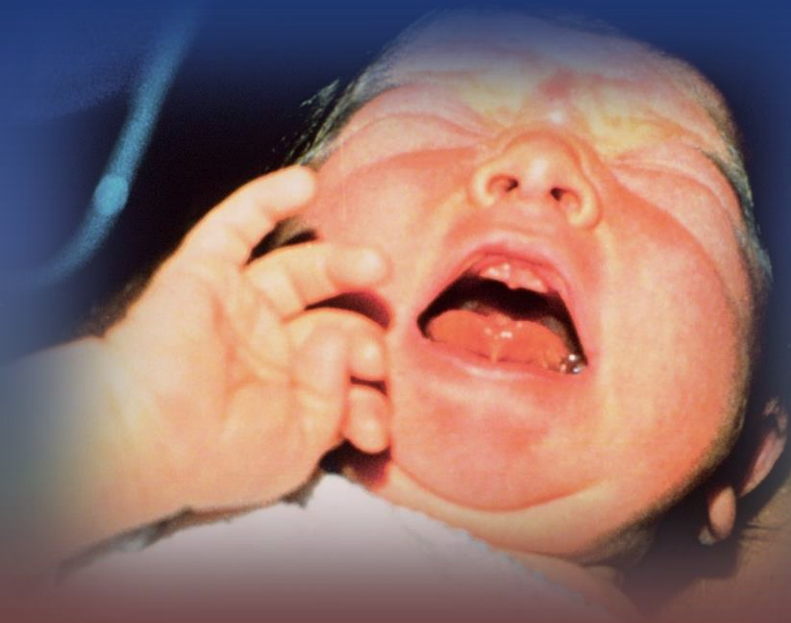
Attachment of Lingual Frenulum to Tongue Underside

2: Posterior to tip

1: At tip

0: Notched OR under the mucosa at the tongue base



1

2

3

S

C

F

f1

f2

f3

f4

f5

f6

f7

A

a1

a2

a3

a4

a5

S

B

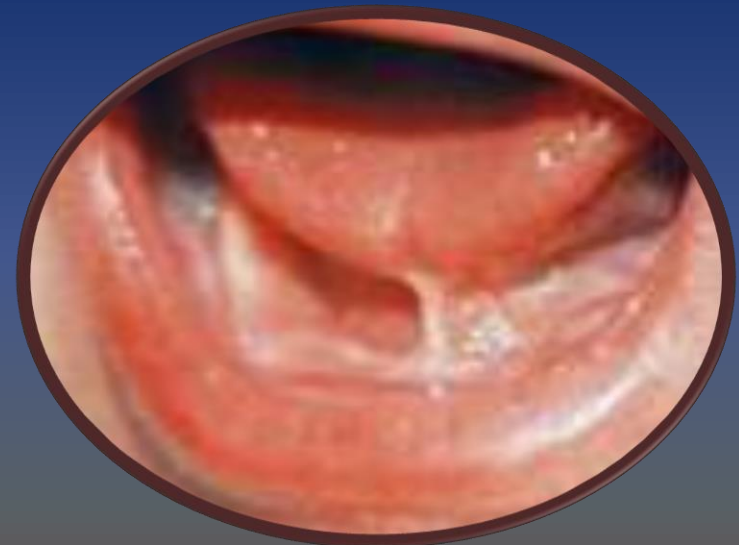
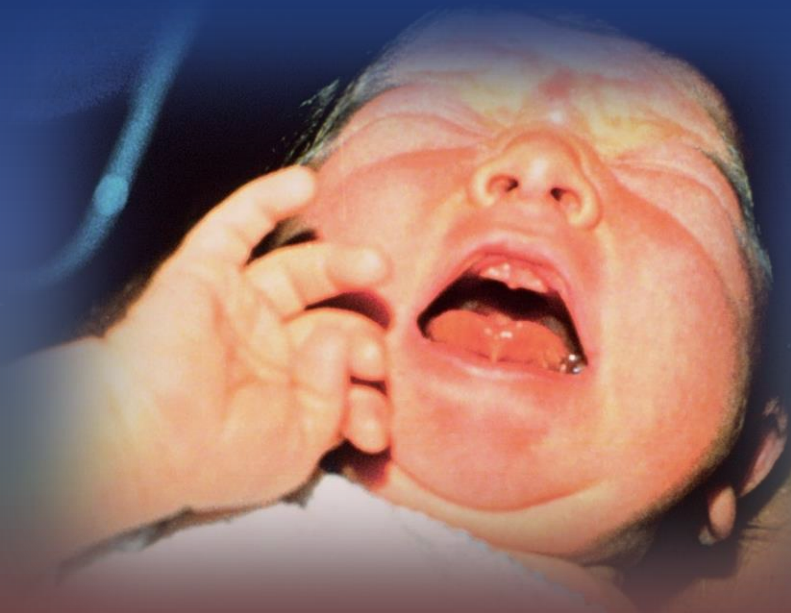Q

Attachment of Lingual Frenulum to Inferior Alveolar Ridge

2: Attached to floor of mouth OR well below ridge

1: Attached just below ridge

0: Attached to ridge



1

2

3

S

C

F

f1

f2

f3

f4

f5

f6

f7

A

a1

a2

a3

a4

a5

S

B

Q

SCORING

- Perfect function
- Regardless of appearance

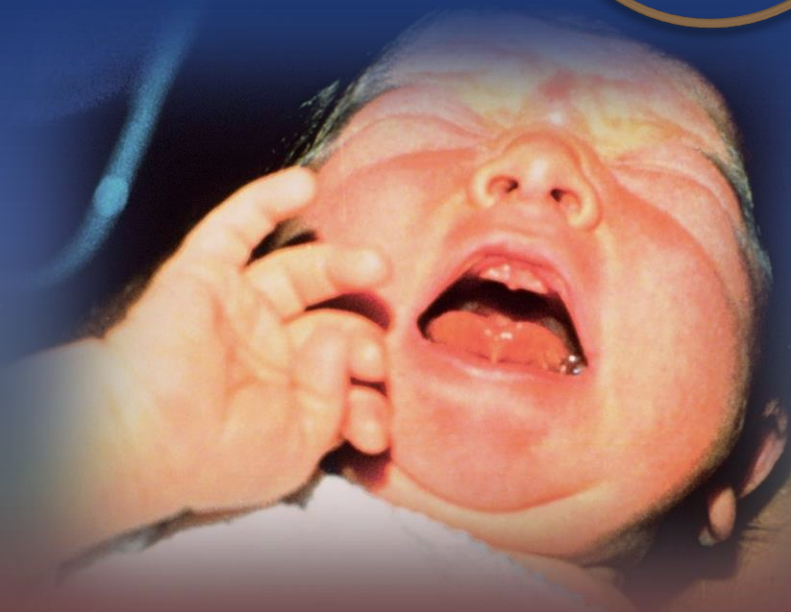14 Function

11 Function
10 Appearance

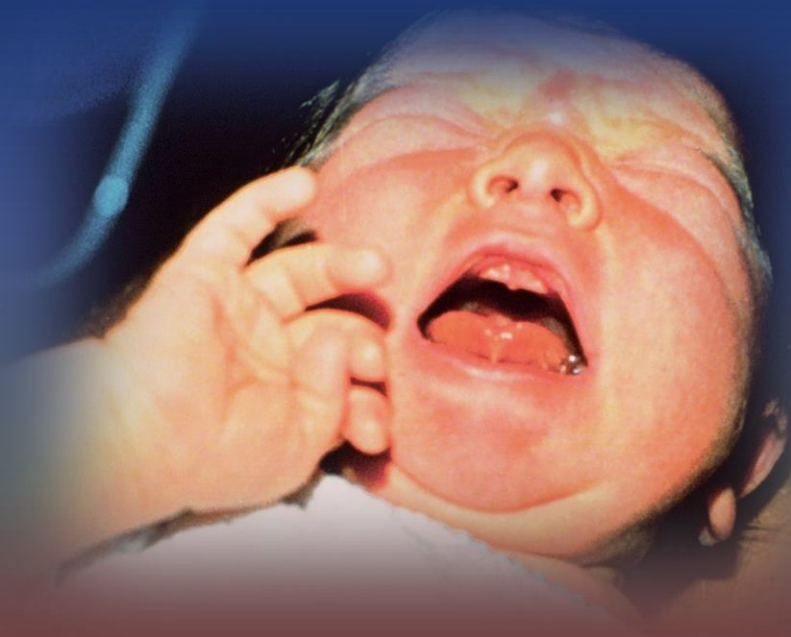- Acceptable function
- Look for alternate cause

- Function impaired
- Frenotomy recommended

< 11 Function
< 8 Appearance



SCORING	
Function Item score: _____	Combined Score: _____ / _____
Appearance Item score: _____	
Treatment Recommendations Based on Scoring	
14 - Perfect Function score regardless of Appearance Item score. Surgical treatment not recommended.	
11 - Acceptable Function score only if Appearance Item score is 10.	
<11 - Function Score indicates function impaired. Frenotomy should be considered if management fails. Frenotomy necessary if Appearance Item score is < 8.	



TONGUE-TIED OR NOT?

1

2

3

S

C

F

f1

f2

f3

f4

f5

f6

f7

A

a1

a2

a3

a4

a5

S

B

Q



TONGUE-TIE

MORPHOGENESIS, IMPACT, ASSESSMENT AND TREATMENT



ALISON K. HAZELBAKER

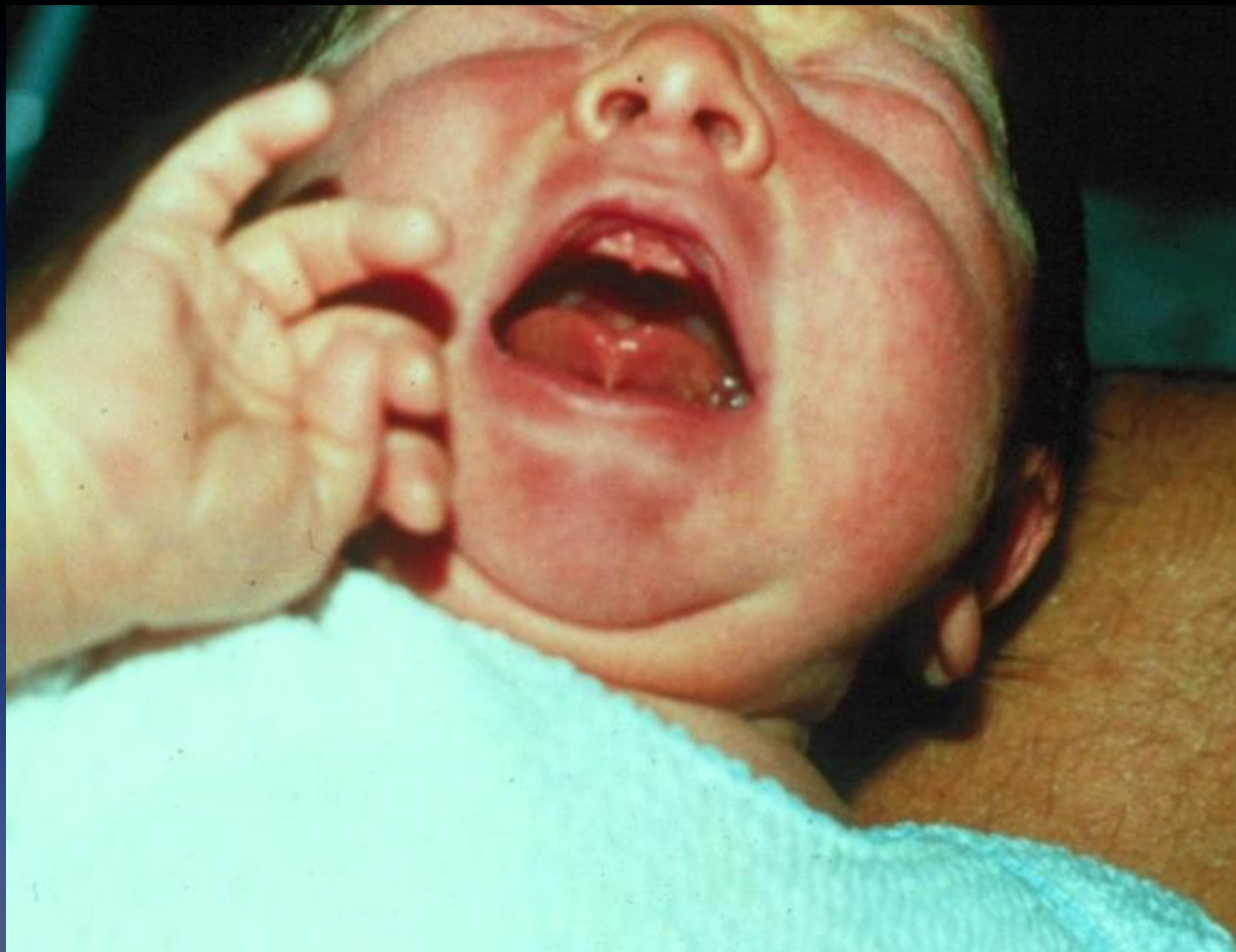PhD, IBCLC, CST, RCST

For Sale
614-451-1154

**GET YOUR BOOK
SIGNED!**

- 1
- 2
- 3
- S
- C
- F
- f1
- f2
- f3
- f4
- f5
- f6
- f7
- A
- a1
- a2
- a3
- a4
- a5
- S
- B
- Q





QUESTIONS

To clip

THE HAZELBAKER ASSESSMENT TOOL FOR LINGUAL FRENULUM FUNCTION

1

2

3

S

C

F

f1

f2

f3

f4

f5

f6

f7

A

a1

a2

a3

a4

a5

S

B

Q

